


**PATIENT**

Blue Phillips

**PRESENTING CLINICAL SIGNS**

History: Grade 5/6 heart murmur. Assess prior to dental.

**SPECIES**

Canine

**ECHOCARDIOGRAM FINDINGS**

2D, m-mode, color flow and doppler imaging is available. Mild diffuse thickening of mitral valve leaflets with no prolapse into the left atrial lumen. Mild eccentric mitral regurgitation with no left atrial dilation. Normal MR velocity. Normal LV diameter with adequate myocardial function. The tricuspid valve appears normal with no tricuspid regurgitation. Normal right atrial and ventricular diameter and morphology indicating no overt evidence of pulmonary arterial hypertension. The pulmonic and aortic valves are normal in morphology and mobility. Normal pulmonic and aortic outflow velocities with laminar flow. No obvious aortic or pulmonic insufficiency. No pericardial or pleural effusion noted. No obvious cardiac masses.

**BREED**

Boston Terrier

**SEX**

Male Neutered

**CARDIAC CHART**
**AGE**

7 years

**WEIGHT**

30.6lbs

**INTERPRETED BY**

 Maggie Machen Lamy,  
 DVM DACVIM  
 (Cardiology)

**IMAGING**
**PERFORMED BY**

Kelly Reschny, RVT

**HOSPITAL NAME**

 East Credit Veterinary  
 Hospital

**REFERRING VET**

Dr. Webster

**INVOICE**

32468

**DATE**

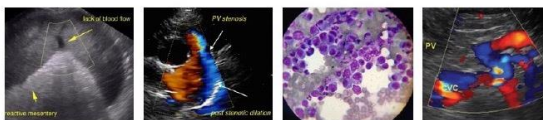
8/22/23

CANINE CARDIAC PARAMETERS	MR VMAX (m/s)	TR VMAX (m/s)	LA/AO (Boon method)	LA/AO (Heart Base; Swe)	FS (%)	EF (%)	EPSS (cm)
<b>NORMAL PARAMETER</b>	4.5-5.5	<2.7	1.3	<1.6	28-40	40-100	<0.6
<b>PATIENT</b>	4.9	NA	1.3	1.1	42	74	0.3
CANINE CARDIAC PARAMETERS	HR (BPM)	AV VMAX (m/s)	PV MAX (m/s)	BODY WEIGHT (kg)	LA 2D short axis Base view (cm)	LVIDd Avg: 2D and m-mode short axis (cm)	LVIDs Avg: 2D and m-mode short axis (cm)
<b>NORMAL PARAMETER</b>	50-100	0.7-1.7	0.7-1.6	BELOW	BELOW	BELOW	BELOW
<b>PATIENT</b>	130	1.6	0.9	13.9	2.0	2.9	1.7
*Normal chamber parameters expressed as a mean value (SD)				3	1.27 (5.3)	2.46 (2.46)	1.36 (5.5)
<b>BODY WEIGHT DEPENDENT PARAMETERS</b>				5	1.40 (4.5)	2.74 (5.2)	1.60 (4.7)
*Note: All measurements based upon multi-modal images and methods. An average value is reported.				10	1.50 (3.8)	3.27 (3.5)	2.06 (3.1)
				15	1.83 (2.0)	3.71 (2.4)	2.43 (2.1)
				20	2.02 (1.9)	4.14 (2.2)	2.80 (2.0)
				25	2.18 (2.4)	4.48 (2.9)	3.10 (2.5)
				30	2.33 (3.3)	4.83 (3.9)	3.39 (3.4)
				35	2.48 (4.3)	5.17 (5.0)	3.69 (4.5)
				40	2.62 (5.2)	5.48 (6.1)	3.96 (5.4)
				50	2.88 (7.1)	6.07 (8.3)	4.46 (7.4)

**INTERPRETATION OF THE FINDINGS & FURTHER RECOMMENDATIONS**

Chronic degenerative valve disease causing mild mitral regurgitation. Lack of significant left atrial enlargement indicates the current risk for complication is low. No concurrent issues such as systolic dysfunction or pulmonary hypertension are noted in this study.

In an asymptomatic dog with no significant left atrial enlargement, no cardiac medications are clearly indicated. Assessment of progression in the future will help predict long term prognosis, which is highly variable at this stage. Omega fatty acid supplementation and mild salt restriction may be of some long-term benefit. Monitor for development of a cough, labored breathing, exercise intolerance or collapse episodes.



**PATIENT**

Blue Phillips

Anesthetic risk is considered mild if needed. Cardiac protective drug choices (opioid/benzodiazepine premedication, propofol or alfaxalone induction, isoflurane gas) are recommended. Pre-oxygenate for 5-10 minutes prior to induction. Monitor for arrhythmias, hypotension, and hypoxia both intra and post-operatively and intervene as necessary. Mild IV fluid restriction is recommended to avoid fluid overload. Avoid heart rate stimulating drugs such as atropine unless clinically indicated.

**SPECIES**

Canine

**BREED**

Boston Terrier

Recommend conservative monitoring with a recheck echocardiogram in 6-12 months, sooner if any development of clinical signs.

**SEX**

Male Neutered

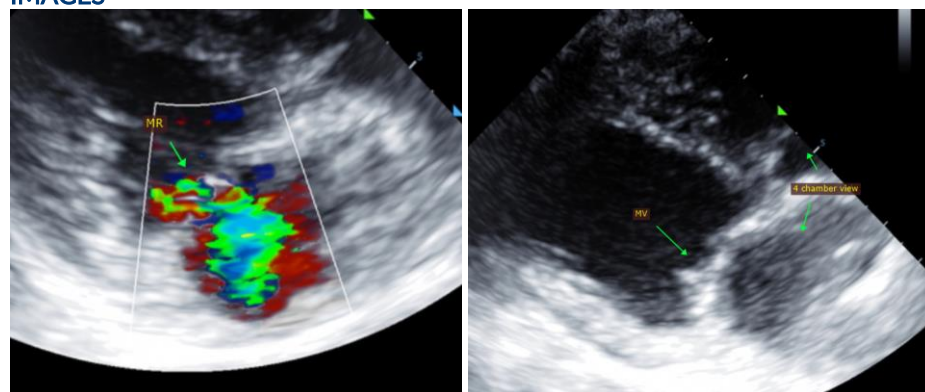
**AGE**

7 years

**WEIGHT**

30.6lbs

**IMAGES**



**INTERPRETED BY**

Maggie Machen Lamy,  
DVM DACVIM  
(Cardiology)

The information and recommendations provided are based on the images presented by the referring veterinarian. No evaluation can be communicated regarding pathology that was not visible in the image/video clips provided.

**IMAGING PERFORMED BY**

Kelly Reschny, RVT

Thank you for this referral. This report was generated using transcription software, and minor dictation errors may be present. If the clinical or image interpretation does not parallel your findings or if I can be of any further assistance, please contact me.

**Maggie Machen Lamy, DVM**  
Diplomate of the American College of Veterinary Internal Medicine (Cardiology)  
info@sonopath.com

**HOSPITAL NAME**

East Credit Veterinary  
Hospital

**REFERRING VET**

Dr. Webster

**INVOICE**

32468

**DATE**

8/22/23